



Case Report

# Rheumatic heart disease and congestive heart failure in antenatal mother: A case report

Jaya Menon<sup>1</sup>, Jane Abishak J<sup>2</sup>, Mariya Jencia P<sup>3</sup>, Jenofia<sup>4</sup>

<sup>1</sup>Nursing Superintendent, Heartcity, Kauvery Hospital, Trichy, Tamil Nadu

<sup>2</sup>Nursing Supervisor, Heart city, Kauvery Hospital, Trichy, Tamil Nadu

<sup>3</sup>Clinical Ward Senior Staff, Heartcity, Kauvery Hospital, Trichy, Tamil Nadu

<sup>4</sup>Nurse Educator, Heartcity, Kauvery Hospital, Trichy, Tamil Nadu

## Abstract

**Background:** Rheumatic Heart Disease (RHD) is a chronic cardiovascular condition resulting from damage to the heart valves following repeated episodes of acute rheumatic fever (ARF), an inflammatory disease triggered by *Streptococcus pyogenes* (group A streptococcal) infections. Ongoing research aims to develop effective vaccines and novel therapeutics to address this preventable yet life-threatening disease.

**Key Words:** Rheumatic Heart Disease (RHD); Acute Rheumatic Fever (ARF); Congestive Heart Failure (CHF)

**Citation:** Jaya Menon, Jane Abishak J, Mariya Jencia P, Jenofia. Rheumatic heart disease and congestive heart failure in antenatal mother: A case report- *Nightingale J.* 2025;1(5):29-34.

Academic Editor: Dr. Venkita S. Suresh



**Copyright:** © 2025 by the authors. Submitted for possible open access publication under the terms and conditions.

## 1. Introduction

Rheumatic Heart Disease (RHD) and Congestive Heart Failure (CHF) post significant risks during pregnancy. RHD caused by rheumatic fever, can lead to valve damage, particularly mitral stenosis which becomes more problematic during pregnancy due to increased blood volume and cardiac output. This can result in heart failure and other complications for both the mother and the fetus.

## 2. Impact of RHD and CHF on pregnancy

### Increased Maternal Mortality

Pregnant women with RHD and CHF have a higher risk of maternal death especially if they develop heart failure.

### Preterm Delivery

Both RHD and CHF can lead to premature birth which can have negative consequences for both mother and baby.

### Increased risk of other complications

These include arrhythmias heart failure exacerbation and the need for interventions like balloon valvotomy or valve replacement.

#### 2.1 Fetal Risks

- Preterm birth
- Intrauterine growth restriction(IVRG)
- Fetal distress
- Congenital Heart Defects.
- Increased risk of peri-natal mortality.

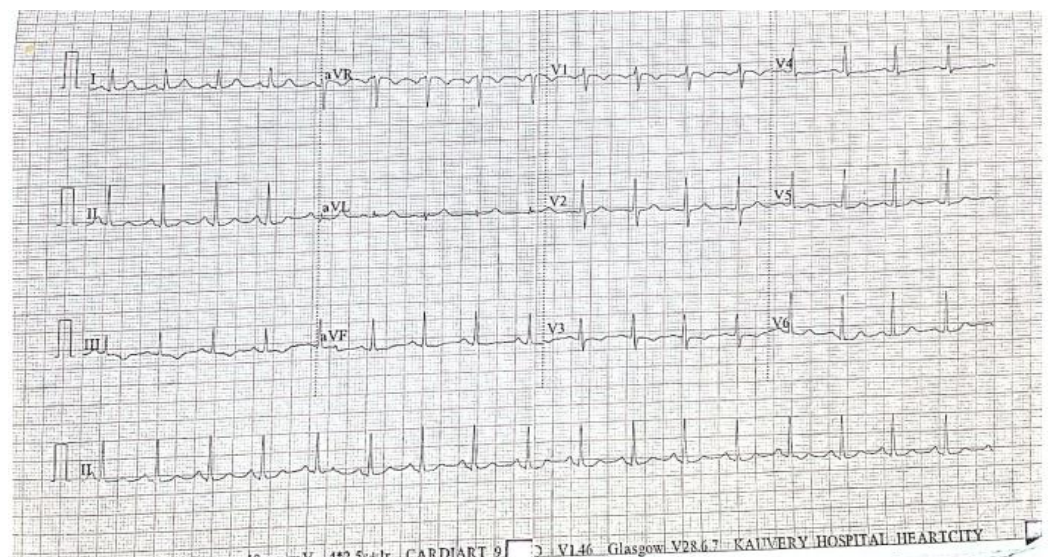
### 3. Case Presentation

A 27 years old antenatal mother is Rheumatic heart disease on treatment. Present with C/O breathing difficulty since today and (Orthopnea) 3.7.25. B/L pedal edema since 1 month, H/O excemine fluid intake since 3 days.

#### 3.1 Diagnosis

He diagnosed as DCDA twin GA 34 weeks 2 days' antenatal mother RHD/ CHF/ Mild TR / MILD MS/ Moderate and severe MR. Patient Plan – Medical management.

#### EKG



### ECHO Report

Patient Details : [REDACTED]	Order No : 3162477
UHID : HC25000016273B	Order Date : 21/02/2025 2:04:22 PM
Report Status : Final	
Visit Details : OPHC00384182	Reported On : 21/02/2025 2:33:35 PM
Referred By : Dr. Anand Subramanian , MD , DM	

**ECHOCARDIOGRAPHIC FINDINGS**

MILD DILATED LA  
 OTHER CHAMBERS NORMAL  
 NO RWMA  
 NORMAL LV SYSTOLIC FUNCTION (EF-62%)

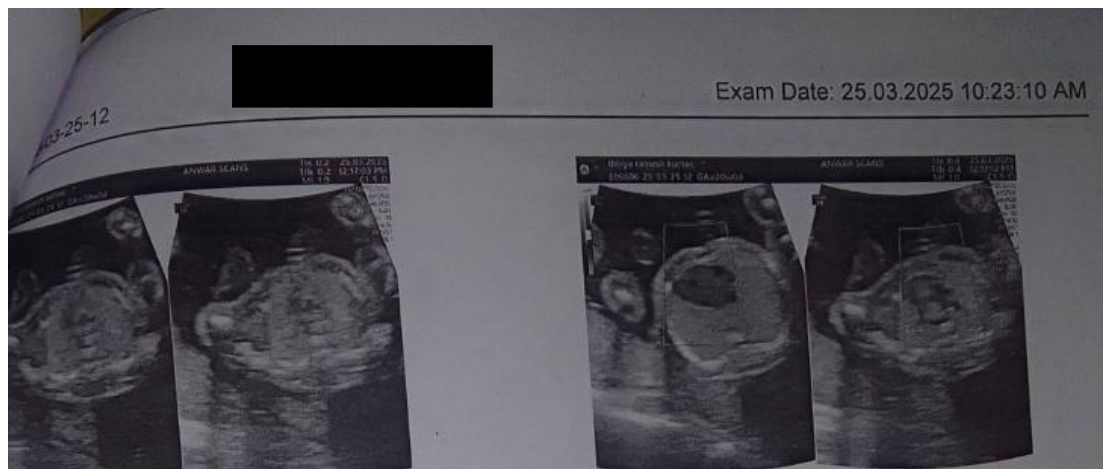
**B/D:**  
 MITRAL VALVE: AML DOMING / PML FIXED  
 MILD MITRAL STENOSIS  
 MVA/2D-2.8cm<sup>2</sup>  
 MVA/PHT-2.0cm<sup>2</sup>  
 MITRAL VALVE GRADIENT-14/8mmHg @ 99BPM  
 MILD MR  
 MONILITY-1, CALCIUM-0, SUB VALVULAR-1

NO TR / PAH  
 SEPTAE INTACT  
 NO PERICARDIAL EFFUSION /CLOT

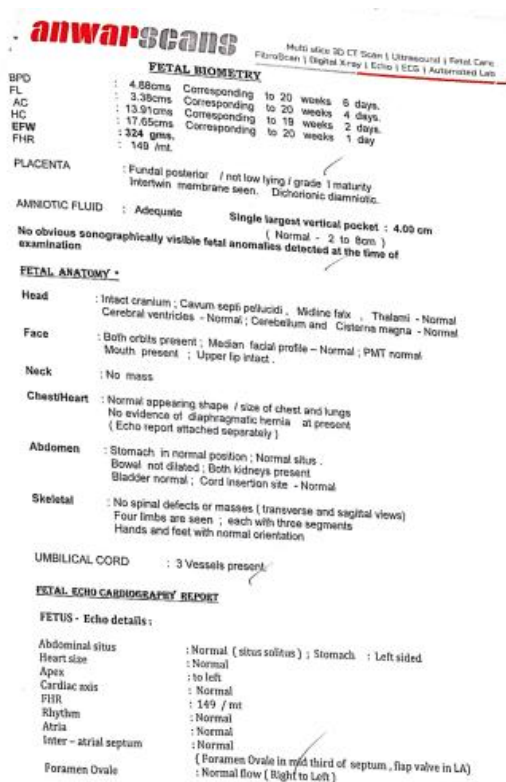
**IMPRESSION**

- RHEUMATIC HEART DISEASE
- MILD MITRAL STENOSIS
- MILD MR
- NORMAL LV SYSTOLIC FUNCTION

### Scan Report



### Fetal Biometry Report



### 4. Course of Stay in Hospital

A 27 years old antenatal mother having history of past illness on rheumatic heart disease for 9 months on treatment. She diagnosed as DCDA twin antenatal mother RHD/CHF/ Mild MS/Moderate Severe MR. She was medical management and investigation for pre op works in LSCS and fitness. Attained for surgery successful LSCS, X Twin baby 05.07.25. She is operative and post-operative hospital stay was uneventful during the post-operative. She was managed with necessary supportive measures. The patient and new born condition improved and is being discharged in a stable hemodynamic status with following advice.

### 5. Pre Op Nursing Management

- Patient for continue cardiac and fetal heart rate monitor.
- Nurses maintained every hourly vitals signs and intake output and assessed neurologically.
- Blood sampling done for pre op investigation under aseptic technique to prevent thrombophlebitis. That is CBC, Blood grouping RFT, Electrolyte, Serology, USG abdomen, Doppler and abdomen screening.
- Doctor advice and explained about risk of procedure to the attender and skin preparation was done and patient was given a provide one bath to minimize the risk of infection.

- NPO instruction were explained to the patient and maintained to ensure an empty to stomach.
- Nurse were provided psychological support.
- Patient was shifted to OT for LSCS.

### 5.1 Post OP Nursing Management

- The patient was transferred the OT to ICU for continue the monitoring.
- Received for new born in NICU for continue monitoring and observation.
- Nurses monitored and maintained vitals signs and reflexes for new born.
- Vitals signs monitoring and surgical site any oozing and skin colour changes observation.
- Using sterile technique to prevent thrombophlebitis.
- The doctors explained the patient and new born condition to attenders.
- Early amputation and mobilization done with helps of nurses.
- All the bundles care followed properly to prevent from hospital acquired infection.
- All suture removed and patient condition improved.
- 3rd POD daily octenison solution bath was given.
- Patient condition improved and she was discharge a stable hemodynamic status for mother and new born.

### 6. Conclusion

Lower segment cesarean section procedure aimed at reducing the risk of patient life threatening. The focus should be on mother and baby. Life savings the immediate surgical intervention but also on long-term health and rehabilitation.

### Reference

- [1] Shawar YR, Shiffman J. Generating Global Priority for Addressing Rheumatic Heart Disease: A Qualitative Policy Analysis. *J Am Heart Assoc.* 2020; 9(8): e014800. DOI: 10.1161/JAHA.119.014800
- [2] Wyber R, Noonan K, Halkon C, et al. Ending rheumatic heart disease in Australia: The evidence for a new approach. *Medical Journal of Australia.* 2020; 213(S10): S3–S31. DOI: 10.5694/mja2.50853
- [3] Katz AM, Phyllis B. Diseases of the heart in the works of Hippocrates. *British Heart Journal.* 1962; 24(3): 257–64. DOI: 10.1136/hrt.24.3.257
- [4] Traill TA. Valvular Heart Disease and Pregnancy. *Cardiology Clinics.* 2012; 30(3): 369–81. DOI: 10.1016/j.ccl.2012.04.004
- [5] McKenzie J. Heart disease and pregnancy. London: Oxford Medical Publications; 1921

- 
- [6] Macdonald A. The bearings of chronic disease of the heart upon pregnancy, par-tuition and childbed. London, UK: J&A Churchill; 1878.
- [7] Mackness G. Heart disease in pregnancy and labour. The Transactions of the Ed-inburgh Obstetrical Society, Ses-sion 1889–1890. XV. Edinburgh: Oliver and Boyd; 1890.
- [8] The Criteria Committee of the New York Heart Association. 1994 Revisions to Classification of Functional Capacity and Objective Assessment of Patients with Diseases of the Heart: NYHA Functional class. In Dolgin M (Ed.), No-menclature and Criteria for Diagnosis of Diseases of the Heart and Great Ves-sels, 253–6. 9th ed. Boston, Mass: Little, Brown & Co; 1994
- [9] Jensen J. The Heart in Pregnancy. London: H. Kimpton; 1938. DOI: 10.1097/00000441-193811000-00035
- [10] Haig D, Gilchrist AR. Heart disease complicated by pregnancy. Trans Edin Obst Soc; 1949.